



# The Open Dentistry Journal

Content list available at: <https://opendentistryjournal.com>



## SYSTEMATIC REVIEW

### Treatment of Peri-implant Diseases using Lasers: A Systematic Review

Amna Mohamed Abdulla AlMarzooqi<sup>1</sup>, Srinivas Sulugodu Ramachandra<sup>1,\*</sup>, Bhavna Jha Kukreja<sup>1</sup>, Sesha Reddy<sup>1</sup>, Jovita Lawrence D. Souza<sup>1</sup> and Hossam Abdelatty Eid Abdelmagyd<sup>1,2</sup>

<sup>1</sup>Preventive Dental Sciences Department, College of Dentistry, Gulf Medical University, Ajman, UAE

<sup>2</sup>Oral Medicine and Periodontology Department, Faculty of Dentistry, Suez Canal University, Ismailia, Egypt

#### Abstract:

##### Background:

Adjuncts to mechanical debridement, including administration of systemically and locally delivered antimicrobials, are constantly evaluated to achieve additional benefits while treating peri-implantitis. However, the potential for the development of antimicrobial resistance limits their use. Evaluation of the use of lasers for the treatment of peri-implantitis has provided varying results.

##### Objective:

This study aimed to summarize the existing literature on the additional benefits of lasers as adjuncts to mechanical debridement while treating peri-implant diseases.

##### Methods:

Randomised clinical trials published in English till Sept 2022 in PubMed, Medline, and clinical trial registries using the MeSH terms “peri-implant diseases”, “peri-implant mucositis”, “peri-implantitis”, and “lasers”, were included in the study. Case reports, case series, longitudinal studies, and retrospective analysis were excluded.

##### Results:

A total of fifteen (n=15) randomised clinical trials pertaining to peri-implantitis and three (n=3) trials pertaining to peri-implant mucositis were assessed. The trials assessed the use of diode, Nd: YAG, Er:YAG, CO<sub>2</sub> lasers, and photodynamic therapy as adjuncts in the treatment of peri-implant diseases.

##### Conclusion:

The existing evidence regarding the use of laser for peri-implant mucositis is inconclusive, whereas for peri-implantitis, the majority of the studies support the use of lasers. Future trials should utilize the 2018 classification of peri-implantitis, so that a comparison of trials based on the studied parameters would be more accurate.

**Keywords:** Peri-implantitis, Peri-implant mucositis, Lasers, Photodynamic therapy, Lasers, Antimicrobial.

#### Article History

Received: November 18, 2022

Revised: April 05, 2023

Accepted: April 11, 2023

## 1. INTRODUCTION

Implant-supported prostheses have become a common method for replacing missing teeth [1, 2]. Achieving and subsequently maintaining osseointegration (bone tissue regeneration over the surface of the implant) is important for the stabilization and long-term success of implants [3]. Loss of implants can occur due to several reasons, including peri-

implant diseases [4]. The term peri-implant diseases encompasses both the terms, peri-implant mucositis and peri-implantitis [4]. Peri-implant mucositis is characterized by erythema and bleeding on the probing of the peri-implant mucosa [4]. This reversible condition is equivalent to gingivitis and may have increased probing depths due to the swelling of the marginal gingiva; however, alveolar bone loss is absent [4]. Contrarily, peri-implantitis is the irreversible inflammation occurring in the peri-implant tissues, caused by subgingival microbial dysbiosis resulting in alveolar bone loss [5, 6]. It is

\* Address correspondence to this author at the Preventive Dental Sciences Department, College of Dentistry, Gulf Medical University, Ajman, UAE; Tel: +971 506636917; E-mail: [srinivas@gmu.ac.ae](mailto:srinivas@gmu.ac.ae)

characterized by bleeding on probing, suppuration and/or erythema, deep pockets, and alveolar bone loss [4]. Increased probing depths as detected by a plastic periodontal probe around implants [7] and alveolar bone loss are the characteristic features of peri-implantitis [8]. Mobility of implants may be noticed in advanced stages of peri-implantitis, which may result in the loss of the implant or may necessitate additional surgical procedures resulting in additional expenses for the patient [4, 5].

The prevalence of peri-implant mucositis according to implant and subject-based evaluation was reported to be 29.48% and 46.83%, respectively [9]. Similarly, the prevalence of peri-implantitis according to implant and subject-based evaluation was reported as 9.25% and 19.83% respectively [9]. Another study by Renvert *et al.* reported the prevalence of peri-implant mucositis and peri-implantitis as 54.7% and 22.1%, respectively [8]. Placing implants into fresh extraction sockets [2, 10], immediate loading of implants [11], implant placement in areas with low bone density (D3 and D4 type of bone) [12], and placement of implants among smokers and uncontrolled diabetics [12], are some of the situations with high rates of peri-implant diseases. Due to the common occurrence of peri-implant diseases and the possible associated complications, these conditions are of high significance. Early identification and ideal intervention for these conditions may prolong the longevity of the implants.

Several treatment options have been explored for the treatment of peri-implantitis. Periodontal debridement mechanically with plastic curettes, saline irrigation, implantoplasty, and access surgery with periodontal debridement, followed by resective or regenerative therapies, are commonly employed [13, 14]. The placement of soft-tissue autografts and allografts has been utilized in the treatment of soft-tissue deficiencies around implants [15, 16]. Several systemic and topical antimicrobials have also been utilized as adjuncts to mechanical therapy while treating peri-implantitis [17, 18]. However, concerns regarding the possible development of antimicrobial resistance with the use of antimicrobials limit their utilization in localized biofilm-related infections. Hence, other treatment options, like lasers (light amplification by stimulated emission of radiation), have been advocated as adjuncts to mechanical therapy [19].

The literature regarding the use of lasers as adjuncts to mechanical therapy for peri-implant diseases has revealed few studies showing improvement in the clinical and microbiological parameters, whereas other studies have shown no additional benefits with lasers being used as an adjunct to mechanical therapy [19, 20]. Different types of lasers, including erbium:yttrium aluminum garnet (Er:YAG), CO<sub>2</sub>, and diode lasers are utilized as adjuncts to mechanical therapy in the treatment of peri-implant diseases [20]. However, a report

summarizing the existing literature regarding peri-implant diseases is currently lacking. Hence, this systematic narrative review aimed to summarize the existing literature regarding laser use in the treatment of peri-implant diseases.

## 2. METHODOLOGY

A literature search was undertaken using the MeSH terms “peri-implantitis”, “peri-implant mucositis”, and “lasers” in PubMed, Medline, and clinical trial registries up to September 2022. Randomised clinical trials in the English language evaluating the additional benefits (if any) of lasers as adjuncts to mechanical therapy in peri-implant diseases were included. Assessment of probing/pocket depths was considered as inclusion criteria for studies evaluating both peri-implant mucositis and peri-implantitis. As an inclusion criterion, for peri-implant mucositis, a minimal follow-up of three months was essential, whereas for peri-implantitis, a minimal follow-up of six months was needed. Case reports, case series, longitudinal studies, and retrospective analysis were excluded from the review. Translating articles published in languages other than English needs additional time and funding. Hence, research studies published in languages other than English were excluded.

## 3. RESULTS

Following the initial search, a total of 353 articles and 27 registrations were identified in PubMed and clinical trial registries (<https://clinicaltrials.gov/>), respectively. Duplicate records of *in vitro* studies, systematic reviews and meta-analyses, and best evidence reviews were excluded. The summary of the included and excluded studies and the reasons for exclusion have been included in the Preferred Reporting Items for Systematic Reviews and Meta-Analyses (PRISMA) flowchart (Fig. 1). A total of 18 randomised clinical trials have been undertaken to assess the additional benefits of lasers as adjuncts to mechanical therapy. Among these trials, the majority of the clinical trials have been on peri-implantitis (n=15) and few trials (n=3) have been carried out on peri-implant mucositis. Among the three trials on peri-implant mucositis, two of the trials did not show additional benefits of using lasers as an adjunct to mechanical therapy. Table 1 summarizes the results of randomised clinical trials evaluating the benefits of lasers as an adjunct treatment to mechanical therapy for peri-implant mucositis. Among the fifteen (n=15) clinical trials conducted on peri-implantitis and lasers, the results of the majority of the clinical trials (n=10) showed additional benefits of using lasers as adjuncts to mechanical therapy. Another five (n=5) trials did not show additional benefits of using lasers as adjuncts to mechanical therapy. Table 2 summarizes the results of randomised clinical trials assessing the benefits of lasers as an adjunct to mechanical debridement for peri-implantitis.

**Table 1. Summary of randomised clinical trials evaluating the use of lasers as adjuncts to mechanical therapy in the treatment of peri-implant mucositis.**

No.	Author/Year	Follow-up Period	Lasers Assessed	No. of Implants in no. of Patients	Primary and Secondary Outcomes	Changes in Pocket/Probing Depth at Baseline and Follow-up Appointments	Conclusion of the Trial
1	Tenore <i>et al.</i> , 2020 [21]	3 months	<b>Diode laser</b> wavelength: 980 nm; power: 1W; energy density: 14.1 J/cm <sup>2</sup>	Twenty three (n=23) implants in twenty three (n=23) patients	Bleeding on probing and probing depths	Pocket/probing depth changes in the laser group: 4.04 ± 0.54 mm at baseline 2.98 ± 0.70 mm at 3 months Pocket depth changes in the control group: 3.8 ± 1.24 mm at baseline 3.54 ± 0.35 mm at 3 months	Significant improvement in probing depths was noticed with the use of diode lasers.
2	Mariani <i>et al.</i> , 2020 [22]	12 months	<b>Diode laser</b> wavelength: 980 nm; power: 2.5 W; energy density: 120 J/cm <sup>2</sup>	Seventy three (n=73) implants in seventy three (n=73) patients	Bleeding on probing and probing depth	Pocket depth changes in the laser group: 3.6 ± 0.7 mm at baseline 3.0 ± 0.6 mm at 3 months 3.1 ± 0.7 mm at 12 months; Pocket depth changes in the control group: 3.8 ± 0.6 mm at baseline 3.1 ± 0.4 mm at 3 months 3.3 ± 0.6 mm at 12 months	Minimal benefits with diode laser used as an adjunct to mechanical debridement.
3	Aimetti <i>et al.</i> , 2019 [23]	3 months	<b>Diode laser</b> wavelength: 980 nm; power: 2.5 W; energy density: 120 J/cm <sup>2</sup>	Two hundred and twenty-two (n=222) implants in two hundred and twenty-two (n=222) patients	Bleeding on probing and pocket depth	Pocket depth changes in the laser group: 3.5 ± 0.7 mm at baseline 3.0 ± 0.5 mm at 1 months 2.9 ± 0.6 mm at 3 months; Pocket depth changes in the control group: 3.4 ± 0.9 mm at baseline 2.9 ± 0.8 mm at 3 months 3.0 ± 0.7 mm at 12 months	No significant additional benefits with the use of diode laser.

**Table 2. Summary of randomised clinical trials evaluating the use of laser therapy as an adjunct to mechanical therapy in the treatment of peri-implantitis.**

No.	Author/Year	Follow-up Period	Lasers Assessed	No. of Implants in no. of Patients	Primary and Secondary Outcomes	Changes in Pocket/Probing Depth at Baseline and Follow-up Appointments	Conclusion of the Trial
1	Rocuzzo <i>et al.</i> , 2022 [24]	6 months	<b>Diode laser</b> wavelength: 810 nm; power: 2.5 W; energy density: not mentioned	Twenty-five (n=25) implants in twenty-five (n=25) patients	Probing pocket depth; clinical, microbiological, and radiographic outcomes.	Pocket depth changes in the laser group: 5.4 ± 0.8 mm at baseline 4.3 ± 0.6 mm at 3 months 4.1 ± 0.8 mm at 6 months; Pocket depth changes in the control group: 5.3 ± 0.5 mm at baseline 3.7 ± 0.6 mm at 3 months 3.8 ± 0.9 mm at 6 months	No additional benefits with the adjunct use of a diode laser

(Table 4) contd.....

No.	Author/Year	Follow-up Period	Lasers Assessed	No. of Implants in no. of Patients	Primary and Secondary Outcomes	Changes in Pocket/Probing Depth at Baseline and Follow-up Appointments	Conclusion of the Trial
2	Yayli <i>et al.</i> , 2022 [25]	6 months	<b>Diode laser</b> wavelength: 940 nm; power: 0.8 W; energy density: 3J/ cm <sup>2</sup> <b>Er,Cr:YSGG laser</b> wavelength: 2780 nm; power: 1.5 W; energy density: not mentioned	Fifty (n=50) implants in fifty (n=50) patients	Probing pocket depth; TIMP-1, MMP-9, gingival index, bleeding on probing	Pocket depth changes in the diode laser group: 4.1 ± 0.8 mm at baseline 3.3 ± 1.0 mm at 6 months; Pocket depth changes in the Er,Cr:YSGG group: 4.5 ± 1.1 mm at baseline 3.3 ± 0.9 mm at 6 months; Pocket depth changes in the control group: 4.1 ± 0.6 mm at baseline 3.6 ± 0.7 mm at 6 months	Er,Cr:YSGG laser was more effective, especially in improving the clinical and molecular parameters
3	Strauss <i>et al.</i> , 2021 [26]	12 months	<b>Nd:YAG</b> wavelength: 1064 nm; power: 3.6 W, 20mHz; energy density: 4J/mm	Thirty six (n=36) implants in twenty (n=20) patients	Probing pocket depth; residual bone levels and bleeding on probing	Pocket depth changes in the laser group: 6.5 mm at baseline 4.6 mm at 12 months; Pocket depth changes in the control group: 5.3 mm at baseline 4.0 mm at 12 months	Significant reductions in probing depth and improvement in bone levels following the use of Nd:YAG lasers
4	Wang <i>et al.</i> , 2021 [27]	6 months	<b>Er:YAG laser</b> wavelength: 2940 nm; power: not mentioned; energy density: 30 mJ/pulse, 20 pulse per sec	Twenty four (n=24) implants in twenty four (n=24) patients	Probing pocket depth; clinical attachment level	Pocket depth changes in the laser group: 7.7 ± 1.9 mm at baseline 6 ± 1.6 mm at 3 months 5.0 ± 1.7 mm at 6 months; Pocket depth changes in the control group: 6.4 ± 1.0 mm at baseline 5 ± 0.8 mm at 3 months 4.6 ± 0.7 mm at 6 months	Er:YAG laser may result in a reduction in probing depths in combination with regenerative periodontal therapy

(Table 4) contd....

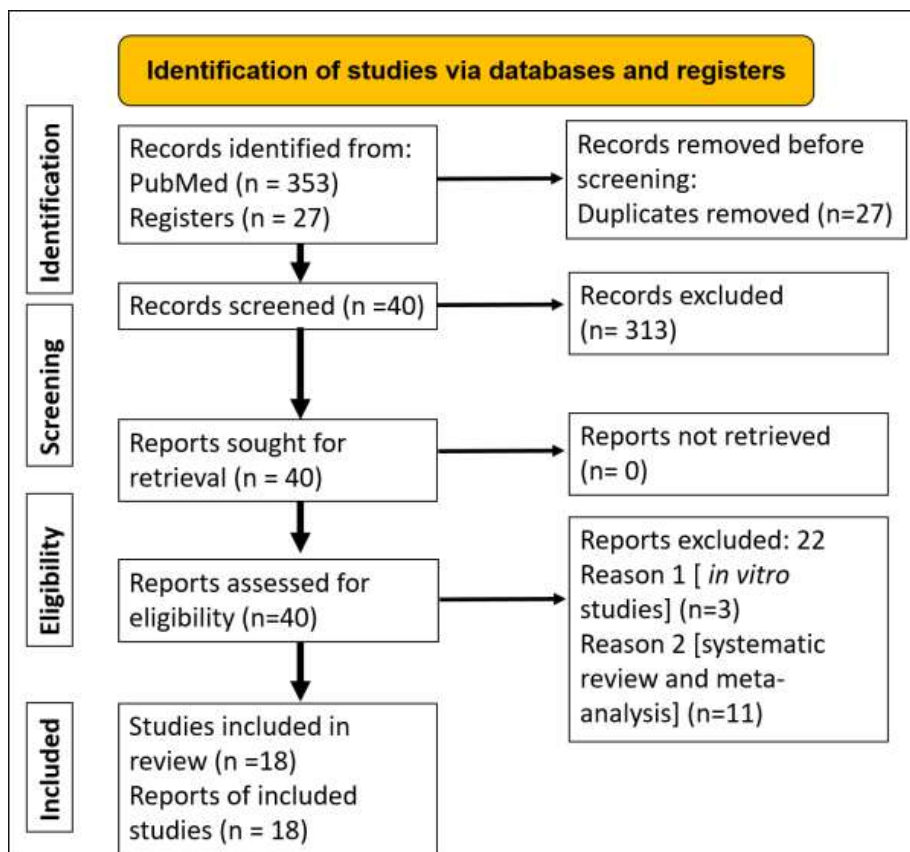
No.	Author/Year	Follow-up Period	Lasers Assessed	No. of Implants in no. of Patients	Primary and Secondary Outcomes	Changes in Pocket/Probing Depth at Baseline and Follow-up Appointments	Conclusion of the Trial
5	Almohareb <i>et al.</i> , 2020 [28]	12 months	<b>Methylene blue mediated using diode laser: photodynamic therapy (PDT)</b> wavelength: 670 nm; power: not mentioned; energy density: not mentioned	Forty (n=40) implants in forty (n=40) patients	Bleeding on probing, probing depth, clinical attachment level, microbial counts of red-complex bacteria	Pocket depth changes in the laser group: 5.2 ± 2.0 mm at baseline 4.4 ± 1.1 mm at 6 months 3.8 ± 0.9 mm at 12 months; Pocket depth changes in the control group: 5.4 ± 2.1 mm at baseline 4.7 ± 1.0 mm at 6 months 4.1 ± 1.0 mm at 12 months	PDT was effective in reducing the symptoms of severe peri-implantitis
6	Alqahtani <i>et al.</i> , 2020 [29]	6 months	<b>Low-level laser therapy</b> wavelength: 940 nm; power: 0.3W; energy density: 3.41J/cm <sup>2</sup>	Sixty-seven (n=67) implants in sixty-seven (n=67) patients	Bleeding on probing, probing depth and levels of the crestal bone	Pocket depth changes in the low-level laser group: 5.1 mm at baseline 1.5 mm at 3 months 1.8 mm at 6 months; Pocket depth changes in the control group: 5.2 mm at baseline 3.3 mm at 3 months 4.8 mm at 6 months	Low-level laser therapy as an adjunct was more effective in reducing bleeding on probing and pocket depths.
7	Wang <i>et al.</i> , 2019 [30]	6 months	<b>PDT using toluidine blue</b> wavelength: 635 nm; power: 750 mW; energy density: not mentioned	One hundred and thirty-one (n=131) implants in one hundred and thirty-one (n=131) patients	Pocket depth and attachment loss	Pocket depth changes in the PDT group: 4.9 ± 1.0 mm at baseline 4.2 ± 0.9 mm at 1 month 3.4 ± 0.4 mm at 3 months 3.0 ± 0.3 mm at 6 months; Pocket depth changes in the control group: 5.0 ± 0.7 mm at baseline 3.5 ± 0.5 mm at 1 month 3.9 ± 0.2 mm at 3 months 4.6 ± 0.4 mm at 6 months	PDT significantly reduced the pocket depth, gingival bleeding, and clinical attachment loss compared to mechanical debridement alone
8	Arisan <i>et al.</i> , 2015 [31]	6 months	<b>Diode laser</b> wavelength: 810 nm; power: 1W; energy density: 3J/cm <sup>2</sup>	Forty eight (n=48) implants in ten (n=10) patients	Pocket depths and marginal bone loss, microbiology and radiographs	Pocket depth changes in the laser group: 4.7 mm at baseline 4.2 mm at 1 month 4.5 mm at 6 months; Pocket depth changes in the control group: 4.4 mm at baseline 4.0 mm at 1 month 4.2 mm at 6 months	No additional benefits were observed with the adjunct use of laser.

(Table 4) contd....

No.	Author/Year	Follow-up Period	Lasers Assessed	No. of Implants in no. of Patients	Primary and Secondary Outcomes	Changes in Pocket/Probing Depth at Baseline and Follow-up Appointments	Conclusion of the Trial
9	Papadopoulos <i>et al.</i> , 2015 [32]	6 months	<b>Diode laser</b> wavelength: 980 nm; power: 0.8W; energy density: not mentioned	Sixteen (n=16) implants in sixteen (n=16) patients	Pocket depth, clinical attachment level, and bleeding on probing.	Pocket depth changes in the laser group: 5.9 mm at baseline 4.5 mm at 3 months 4.4 mm at 6 months; Pocket depth changes in the control group: 5.5 mm at baseline 4.3 mm at 3 months 4.4 mm at 6 months	Additional use of diode laser with access surgical therapy did not provide additional benefits.
10	Bombeccari <i>et al.</i> , 2013 [33]	6 months	<b>PDT</b> wavelength: 810 nm; power: 1W; energy density: not mentioned	Forty (n=40) implants in forty (n=40) patients	Bleeding scores, inflammatory exudation, and total anaerobic bacteria	Pocket depth changes in the PDR group: 5.9 ± 0.8 mm at baseline 5.2 ± 1.3 mm at 3 months 4.9 ± 0.5 mm at 6 months; Pocket depth changes in the control group: 5.8 ± 0.8 mm at baseline 5.7 ± 0.5 mm at 3 months 5.5 ± 0.5 mm at 6 months	Bleeding scores and inflammatory exudates were significantly reduced in the PDT group
11	Schwarz <i>et al.</i> , 2011 [34]	6 months	<b>Er:YAG laser</b> wavelength: 2940 nm; power: not mentioned; energy density: 11.4J/cm <sup>2</sup> , 10 Hz	Thirty-eight (n=38) implants in thirty-two (n=32) patients	Bleeding on probing and clinical attachment loss	Pocket depth changes in the laser group: 5.1 ± 1.6 mm at baseline 3.4 ± 0.6 mm at 6 months; Pocket depth changes in the control group: 5.5 ± 1.8 mm at baseline 3.1 ± 0.6 mm at 6 months	The addition of laser therapy to the surgical debridement of peri-implantitis lesions did not provide additional benefits.
12	Schwarz <i>et al.</i> , 2013 [35]	48 months (four-year follow-up)	<b>Er:YAG laser</b> wavelength: 2940nm; power: not mentioned; energy density: 11.4J/cm <sup>2</sup> , 10 Hz	Twenty one (n=21) implants in seventeen (n=17) patients	Bleeding on probing and clinical attachment loss	Pocket depth changes in the laser group: 5.1 ± 1.6 mm at baseline 3.8 ± 1.1 mm at 48 months; Pocket depth changes in the control group: 5.5 ± 1.8 mm at baseline 4.3 ± 1.2 mm at 48 months	No additional benefits with Er:YAG laser use as an adjunct to resective/regenerative periodontal therapy

(Table 4) contd....

No.	Author/Year	Follow-up Period	Lasers Assessed	No. of Implants in no. of Patients	Primary and Secondary Outcomes	Changes in Pocket/Probing Depth at Baseline and Follow-up Appointments	Conclusion of the Trial
13	Schwarz <i>et al.</i> , 2012 [36]	24 months	<b>Er:YAG laser</b> wavelength: 2940nm; power: not mentioned; energy density: 11.4J/cm <sup>2</sup> , 10 Hz	Twenty six (n=26) implants in twenty four (n=24) patients	Bleeding on probing and clinical attachment loss	Pocket depth changes in the laser group: 5.1 ± 1.6 mm at baseline 3.2 ± 0.8 mm at 12 months Pocket depth changes in the control group: 5.5 ± 1.8 mm at baseline 3.2 ± 0.4 mm at 12 months	Use of Er:YAG laser following access surgery was equally effective compared to surface decontamination
14	Bassetti <i>et al.</i> , 2014 [37]	12 months	PDT wavelength: 660 nm; power: 100 mW for 10 sec; energy density: not mentioned	Forty (n=40) implants in forty (n=40) patients	Bleeding on probing, pocket depth, clinical attachment level, microbial counts, and crevicular fluid levels	Pocket depth changes in the PDT group: 4.2 ± 0.5 mm at baseline 3.9 ± 0.6 mm at 3 months 3.8 ± 0.6 mm at 6 months 3.9 ± 0.7 mm at 9 months 4.1 ± 0.8 mm at 12 months; Pocket depth changes in the local drug delivery group: 4.4 ± 0.8 mm at baseline 3.9 ± 0.6 mm at 3 months 3.9 ± 0.8 mm at 6 months 3.9 ± 0.7 mm at 9 months 4.1 ± 0.8 mm at 12 months	The use of PDT was equally effective in reducing all the clinical parameters compared to the local administration of minocycline microspheres
15	Persson <i>et al.</i> , 2011[38]	6 months	<b>Er:YAG laser</b> wavelength: 2940 nm; power: 100mJ, 10Hz; energy density: 12.7 J/cm <sup>2</sup>	Hundred (n=100) implants in forty-two (n=42) patients	The pocket depth and levels of pathogenic periodontal bacteria	Pocket depth changes in the laser group: 6.9 ± 1.4 mm at baseline 5.8 ± 1.5 mm at 6 months; Pocket depth changes in the air abrasive group: 6.5 ± 2.1 mm at baseline 5.2 ± 1.5 mm at 6 months	Short-term reduction (one month) in the levels of pathogenic bacteria in both the laser group and the air-abrasive group. At 6 months, both the groups showed limited improvement.



**Fig. (1).** Preferred reporting items for systematic reviews and meta-analyses (PRISMA) flowchart showing the list of included and excluded studies. The reasons for exclusion are listed.

#### 4. DISCUSSION

Among the three randomised clinical trials undertaken on peri-implant mucositis, with lasers as adjuncts to mechanical therapy, two of the trials failed to show significant benefits compared to mechanical debridement alone. Tenore *et al.* reported significant improvement in probing depths with the use of diode lasers as an adjunct to mechanical debridement of peri-implant mucositis and initial peri-implantitis [21]. This study was followed for three months and the clinical trial had a negative control, which was a positive aspect of the trial [21]. Mariani *et al.* reported a clinical trial involving 73 peri-implant mucositis patients; the adjunct use of diode laser with mechanical debridement resulted in minimal improvement in the clinical parameters [22]. Though the use of a diode laser may provide benefits in the short term, there have been no significant benefits reported in the long term [22]. In another trial comprising 222 implants, the addition of a diode laser did not significantly reduce bleeding on probing or decrease pocket depths compared to mechanical therapy alone at three months [23]. (Table 2) Hence, with regards to peri-implant mucositis, the addition of lasers to mechanical therapy seems to provide minimal additional benefits (if any) compared to mechanical therapy.

The following section highlights the trials that have shown additional benefits of using lasers as adjuncts to mechanical therapy for peri-implantitis. Almohareb *et al.* reported similar improvement in the clinical parameters among severe peri-

implantitis (with abscess) patients at 6 and 12 months by using both antimicrobial (application of amoxicillin and metronidazole) and photodynamic (methylene blue mediated with diode laser) therapies as adjuncts to mechanical therapy [28]. However, the absence of negative control in the trial design (only mechanical therapy) was one of the limitations of the study [28]. Alqahtani *et al.* reported significant improvement in bleeding on probing and pocket depths at three and six months with adjunct low-level laser therapy compared to mechanical therapy alone [29]. However, there was no significant improvement in the crestal bone levels in either of the groups at six months [29]. Another clinical trial on peri-implantitis among Chinese Han patients with the use of photodynamic therapy (635 nm laser with toluidine blue) reported improvements in pocket depth, peri-implant plaque index, bleeding index, and clinical attachment level [30] (Table 2).

Bombeccari *et al.* reported that the use of photodynamic therapy (PDT) resulted in reductions in bleeding index and inflammatory exudates [33]. However, the levels of total anaerobic bacteria were not reduced in the PDT group compared to the surgical therapy alone group [33]. (Table 2) + Bassetti *et al.* reported the use of PDT as effective as the local application of minocycline microspheres in reducing bleeding on probing, pocket depth, and clinical attachment level [37]. Similarly, the levels of pathogenic bacteria and interleukin-1 $\beta$  in the GCF were reduced in both PDT and minocycline microspheres groups [37].



A few clinical trials have reported no additional benefits in clinical or microbiological parameters following the use of lasers with non-surgical mechanical debridement. Arisan *et al.* reported no significant differences in pocket depths, counts of periodontal pathogens, and bone levels in laser and control groups among peri-implantitis patients [31]. Papadopoulos *et al.* reported no significant benefits with diode laser use as an adjunct to surgical therapy [32]. All the clinical parameters, including pocket depth, clinical attachment level, bleeding on probing, and plaque index improved in both the groups [32]. Schwarz *et al.* reported no additional benefits of adjunct surface decontamination using lasers in patients with peri-implantitis [35]. At two years, the same group of patients showed both the therapies to be equally effective with both laser debridement and manual debridement in terms of reducing bleeding on probing and clinical attachment levels [36].

Persson *et al.* reported a short-term reduction (1 month) in the levels of periodontal pathogens in both air-abrasive subgingival polishing and laser groups [38]. However, by six months, both groups failed to show significant improvements in the clinical parameters [38]. The levels of periodontal pathogens were also not reduced in both groups at six months [38]. Peri-implant diseases are multi-factorial with the accumulation of subgingival plaque in the form of biofilm being the initiating factor [39]. Additionally, biofilms have an inherent ability to be resistant to the action of antimicrobials/biocides [40, 41]. The biofilm complex creates an environment wherein bacterial aggregates adhere to the implant surface and each other with a self-produced matrix of extracellular polymer substance [41]. The bacteria in the biofilm possess various properties, including the production of endotoxins and enzymes capable of destroying the adjacent connective tissue and quorum sensing, which ultimately enhances the virulence of the biofilm [39]. Lasers act by reducing the bacterial load at the implant surface by surface decontamination, and they are also known to possess antimicrobial properties [42]. Photodynamic therapy employs a photosensitizer dye which when activated by the laser light results in oxidative damage causing an anti-microbial effect [43]. Moderately rough surfaces of the dental implants could be another reason for peri-implantitis. Currently, most dental implants possess moderately rough surfaces, which if covered by a biofilm are extremely difficult to clean [44]. Various *in vitro* studies have been carried out to explore novel surfaces that may have the ability to enhance the attachment of the cells to the implant-abutment framework and simultaneously reduce bacterial adhesion and microbial contamination [45, 46]. Finally, placement of implants without adequate treatment planning and without acquiring optimal training has also been listed as the cause of mishaps during implant procedures and subsequent peri-implantitis [47 - 49].

#### 4.1. Limitations

This review has a few limitations. Firstly, many of the clinical trials, especially the trials on peri-implantitis, were superior clinical trials, where the efficacy between two types of adjunct therapies (air-abrasive therapy versus laser therapy or adjunct antimicrobial therapy versus laser therapy) was

compared. Additionally, many of these trials also lacked a negative control (placebo) in their trial design, which could be considered a limitation of these trials. Secondly, the trials used different types of lasers with varying treatment protocols. Due to the heterogeneity of data concerning the use of the different types of lasers in peri-implant diseases, it is difficult to arrive at definitive conclusions or perform a meta-analysis on the topic. Thirdly, various case definitions have been used for peri-implant diseases, which acts as a deterrent in comparing the different studies. In 2018, the American Academy of Periodontology and the European Federation of Periodontology jointly released a new classification of peri-implant health and peri-implant diseases [50]. Future research on peri-implantitis should follow universally accepted case definitions of peri-implantitis.

#### 4.2. Future Directions

Only a few clinical trials have reported on the adjunct benefits of lasers in peri-implant mucositis. Possible reasons for the lack of studies on peri-implant mucositis and lasers could be due to the difficulty in identifying patients with peri-implant mucositis and the lack of reporting by patients regarding peri-implant mucositis. However, since peri-implant mucositis is reversible, better methods to treat this condition would be beneficial to patients. So, more high-quality clinical trials are needed on the additional benefits of lasers in the treatment of peri-implant mucositis.

#### CONCLUSION

There is scarce evidence to suggest that lasers as an adjunct to mechanical therapy in peri-implant mucositis provide additional benefits. With regards to peri-implantitis, laser use as an adjunct seems to provide additional benefits, especially with regards to reduction in bleeding on probing, and pocket depths. Although the reduction in the levels of pathogenic bacteria may be short-lived, a few studies report long-term benefits (up to 12 months). Hence, lasers can be used as adjuncts in the treatment of peri-implantitis.

#### LIST OF ABBREVIATIONS

<b>LASER</b>	= Light Amplification by Stimulated Emission of Radiation
<b>PRISMA</b>	= Preferred Reporting Items for Systematic Reviews and Meta-Analyses
<b>PDT</b>	= Photodynamic Therapy
<b>Nd:YAG</b>	= Neodymium-doped Yttrium Aluminum Garnet
<b>Er:YAG</b>	= Erbium-doped Yttrium Aluminium Garnet
<b>Er,Cr:YSGG</b>	= Erbium, Chromium-doped Yttrium, Scandium, Gallium, and Garnet

#### CONSENT FOR PUBLICATION

Not applicable.

#### AVAILABILITY OF DATA AND MATERIALS

This is a systematic review of already published randomised controlled trials on the topic of lasers and peri-implantitis. The data has been retrieved from PubMed database, <https://pubmed.ncbi.nlm.nih.gov/>, [21 - 38].

**FUNDING**

This is a systematic review, and the study did not receive any funds/grants. Article processing fees has been funded by the College of Dentistry, Gulf Medical University, Ajman, UAE.

**STANDARDS OF REPORTING**

PRISMA guidelines were followed for this study.

**CONFLICT OF INTEREST**

All the authors declare no conflict of interest.

**ACKNOWLEDGEMENTS**

Declared none.

**SUPPLEMENTARY MATERIAL**

PRISMA checklist is available as supplementary material on the publisher's website along with the published article.

**REFERENCES**

- [1] Pandey C, Rokaya D, Bhattarai BP. Contemporary concepts in osseointegration of dental implants: A review. *BioMed Res Int* 2022; 2022: 1-11. [http://dx.doi.org/10.1155/2022/6170452] [PMID: 35747499]
- [2] Ramachandra SS, Patil M, Mehta DS. Implants placed into extraction sockets: A literature review. *Dent Implantol Update* 2009; 20(2): 1-8. [PMID: 19216316]
- [3] Tomasi C, Derks J. Etiology, occurrence, and consequences of implant loss. *Periodontol* 2000 2022; 88(1): 13-35. [http://dx.doi.org/10.1111/prd.12408] [PMID: 35103324]
- [4] Renvert S, Persson GR, Pirih FQ, Camargo PM. Peri-implant health, peri-implant mucositis, and peri-implantitis: Case definitions and diagnostic considerations. *J Periodontol* 2018; 89(Suppl. 1): S304-12. [http://dx.doi.org/10.1002/JPER.17-0588] [PMID: 29926953]
- [5] Berglundh T, Armitage G, Araujo MG, *et al.* Peri-implant diseases and conditions: Consensus report of workgroup 4 of the 2017 World Workshop on the Classification of Periodontal and Peri-Implant Diseases and Conditions. *J Clin Periodontol* 2018; 45(Suppl. 20): S286-91. [http://dx.doi.org/10.1111/jcpe.12957] [PMID: 29926491]
- [6] Schwarz F, Derks J, Monje A, Wang HL. Peri-implantitis. *J Clin Periodontol* 2018; 45(Suppl. 20): S246-66. [http://dx.doi.org/10.1111/jcpe.12954] [PMID: 29926484]
- [7] Ramachandra SS, Mehta DS, Sandesh N, Baliga V, Amarnath J. Periodontal probing systems: A review of available equipment. *Compend Contin Educ Dent* 2011; 32(2): 71-7. [PMID: 21473303]
- [8] Renvert S, Lindahl C, Persson GR. Occurrence of cases with peri-implant mucositis or peri-implantitis in a 21-26 years follow-up study. *J Clin Periodontol* 2018; 45(2): 233-40. [http://dx.doi.org/10.1111/jcpe.12822] [PMID: 28963776]
- [9] Lee CT, Huang YW, Zhu L, Weltman R. Prevalences of peri-implantitis and peri-implant mucositis: systematic review and meta-analysis. *J Dent* 2017; 62: 1-12. [http://dx.doi.org/10.1016/j.jdent.2017.04.011] [PMID: 28478213]
- [10] Ramachandra S, Patil M, Mehta DS. Evaluation of implants placed into fresh extraction sockets in the maxillary anterior region: A clinico-radiographic study. *J Dent Implant* 2011; 1(2): 58-63. [http://dx.doi.org/10.4103/0974-6781.91281]
- [11] Cercadillo-Ibarguren I, Sánchez-Torres A, Figueiredo R, Schwarz F, Gay-Escoda C, Valmaseda-Castellón E. Immediately loaded implant-supported full-arches: Peri-implant status after 1-9 years in a private practice. *J Dent* 2017; 67: 72-6. [http://dx.doi.org/10.1016/j.jdent.2017.09.014] [PMID: 28962843]
- [12] Heitz-Mayfield LJ, Aaboe M, Araujo M, *et al.* Group 4 ITI Consensus Report: Risks and biologic complications associated with implant dentistry. *Clin Oral Implants Res* 2018; 29(S16)(Suppl. 16): 351-8. [http://dx.doi.org/10.1111/clr.13307] [PMID: 30328181]
- [13] Karlsson K, *et al.* Efficacy of access flap and pocket elimination procedures in the management of peri-implantitis - a systematic review and meta-analysis. *J Clin Periodontol* 2022. [http://dx.doi.org/10.1111/jcpe.13732]
- [14] Lin CY, Chen Z, Chiang HL, Pan WL, Wang HL. The impact of implantoplasty in regenerated and nonregenerated treatment modalities in peri-implantitis: A systematic review and meta-analysis. *Int J Oral Maxillofac Implants* 2022; 37(5): 859-68. [http://dx.doi.org/10.11607/jomi.9436] [PMID: 36170300]
- [15] Ramachandra SS, Rana R, Reetika S, Jithendra KD. Options to avoid the second surgical site: A review of literature. *Cell Tissue Bank* 2014; 15(3): 297-305. [http://dx.doi.org/10.1007/s10561-013-9395-8] [PMID: 24002077]
- [16] Kocak Oztug NA, Ramachandra SS, Lacin CC, *et al.* Regenerative approaches in periodontics. *Regenerative Approaches in Dentistry*. Cham: Springer 2021. [http://dx.doi.org/10.1007/978-3-030-59809-9\_6]
- [17] Polymeri A, van der Horst J, Ansari Moin D, Wismeijer D, Loos BG, Laine ML. Non-surgical peri-implantitis treatment with or without systemic antibiotics: A randomized controlled clinical trial. *Clin Oral Implants Res* 2022; 33(5): 548-57. [http://dx.doi.org/10.1111/clr.13914] [PMID: 35238084]
- [18] Passarelli PC, *et al.* Local/topical antibiotics for peri-implantitis treatment: A systematic review. *Antibiotics* 2021; 10(11): 1298.
- [19] Monje A, Amerio E, Cha JK, *et al.* Strategies for implant surface decontamination in peri-implantitis therapy. *Int J Oral Implantol (New Malden)* 2022; 15(3): 213-48. [PMID: 36082658]
- [20] Baima G, Citterio F, Romandini M, *et al.* Surface decontamination protocols for surgical treatment of peri-implantitis: A systematic review with meta-analysis. *Clin Oral Implants Res* 2022; 33(11): 1069-86. [http://dx.doi.org/10.1111/clr.13992] [PMID: 36017594]
- [21] Tenore G, Montori A, Mohsen A, Mattarelli G, Palaia G, Romeo U. Evaluation of adjunctive efficacy of diode laser in the treatment of peri-implant mucositis: A randomized clinical trial. *Lasers Med Sci* 2020; 35(6): 1411-7. [http://dx.doi.org/10.1007/s10103-020-03009-y] [PMID: 32304001]
- [22] Mariani GM, Ercoli E, Guzzi N, *et al.* One-year clinical outcomes following non-surgical treatment of peri-implant mucositis with adjunctive diode laser application. *Minerva Stomatol* 2020; 69(5): 269-77. [http://dx.doi.org/10.23736/S0026-4970.20.04340-X] [PMID: 32278340]
- [23] Aimetti M, Mariani GM, Ferrarotti F, Ercoli E, Liu CC, Romano F. Adjunctive efficacy of diode laser in the treatment of peri-implant mucositis with mechanical therapy: A randomized clinical trial. *Clin Oral Implants Res* 2019; 30(5): 429-38. [http://dx.doi.org/10.1111/clr.13428] [PMID: 30933384]
- [24] Rocuzzo A, Klossner S, Stähli A, *et al.* Non-surgical mechanical therapy of peri-implantitis with or without repeated adjunctive diode laser application. A 6-month double-blinded randomized clinical trial. *Clin Oral Implants Res* 2022; 33(9): 900-12. [http://dx.doi.org/10.1111/clr.13969] [PMID: 35775311]
- [25] Alpaslan Yayli NZ, Talmac AC, Keskin Tunc S, Akbal D, Altindal D, Ertugrul AS. Erbium, chromium-doped: Yttrium, scandium, gallium, garnet and diode lasers in the treatment of peri-implantitis: Clinical and biochemical outcomes in a randomized-controlled clinical trial. *Lasers Med Sci* 2022; 37(1): 665-74. [http://dx.doi.org/10.1007/s10103-021-03436-5] [PMID: 34637055]
- [26] Strauss G, Goteiner D, Murawski K, Singer S, Drew H, Sullivan A. Laser-assisted therapy for the treatment of peri-implantitis. Part I. *Int J Periodontics Restorative Dent* 2021; 41(4): 563-8. [http://dx.doi.org/10.11607/prd.5377] [PMID: 34328476]
- [27] Wang CW, Ashnagar S, Gianfilippo RD, Arnett M, Kinney J, Wang HL. Laser-assisted regenerative surgical therapy for peri-implantitis: A randomized controlled clinical trial. *J Periodontol* 2021; 92(3): 378-88. [http://dx.doi.org/10.1002/JPER.20-0040] [PMID: 32761810]
- [28] Almohareb T, Alhamoudi N, Al Deeb M, *et al.* Clinical efficacy of photodynamic therapy as an adjunct to mechanical debridement in the treatment of peri-implantitis with abscess. *Photodiagn Photodyn Ther* 2020; 30: 101750. [http://dx.doi.org/10.1016/j.pdpdt.2020.101750] [PMID: 32545150]
- [29] Alqhtani F, Alqhtani N, Celur SL, Divakar DD, Al-Kheraif AA, Alkhtani F. Efficacy of nonsurgical mechanical debridement with and without adjunct low-level laser therapy in the treatment of peri-implantitis: A randomized controlled trial. *J Oral Implantol* 2020; 46(5): 526-31.

- [30] Wang H, Li W, Zhang D, Li W, Wang Z. Adjunctive photodynamic therapy improves the outcomes of peri-implantitis: A randomized controlled trial. *Aust Dent J* 2019; 64(3): 256-62. [http://dx.doi.org/10.1563/aaid-joi-D-19-00367] [PMID: 32369570]
- [31] Arisan V, Karabuda ZC, Arıcı SV, Topçuoğlu N, Külekçi G. A randomized clinical trial of an adjunct diode laser application for the nonsurgical treatment of peri-implantitis. *Photomed Laser Surg* 2015; 33(11): 547-54. [http://dx.doi.org/10.1111/adj.12705] [PMID: 31152567]
- [32] Papadopoulos CA, Vouros I, Menexes G, Konstantinidis A. The utilization of a diode laser in the surgical treatment of peri-implantitis. A randomized clinical trial. *Clin Oral Investig* 2015; 19(8): 1851-60. [http://dx.doi.org/10.1007/s00784-014-1397-9] [PMID: 25623382]
- [33] Bombeccari GP, Guzzi G, Gualini F, Gualini S, Santoro F, Spadari F. Photodynamic therapy to treat periimplantitis. *Implant Dent* 2013; 22(6): 631-8. [http://dx.doi.org/10.1097/01.id.0000433592.18679.91] [PMID: 24225780]
- [34] Schwarz F, Sahn N, Iglhaut G, Becker J. Impact of the method of surface debridement and decontamination on the clinical outcome following combined surgical therapy of peri-implantitis: A randomized controlled clinical study. *J Clin Periodontol* 2011; 38(3): 276-84. [http://dx.doi.org/10.1111/j.1600-051X.2010.01690.x] [PMID: 21219392]
- [35] Schwarz F, Hegewald A, John G, Sahn N, Becker J. Four-year follow-up of combined surgical therapy of advanced peri-implantitis evaluating two methods of surface decontamination. *J Clin Periodontol* 2013; 40(10): 962-7. [http://dx.doi.org/10.1111/jcpe.12143] [PMID: 23931259]
- [36] Schwarz F, John G, Mainusch S, Sahn N, Becker J. Combined surgical therapy of peri-implantitis evaluating two methods of surface debridement and decontamination. A two-year clinical follow up report. *J Clin Periodontol* 2012; 39(8): 789-97. [http://dx.doi.org/10.1111/j.1600-051X.2012.01867.x] [PMID: 22639800]
- [37] Bassetti M, Schär D, Wicki B, *et al.* Anti-infective therapy of peri-implantitis with adjunctive local drug delivery or photodynamic therapy: 12-month outcomes of a randomized controlled clinical trial. *Clin Oral Implants Res* 2014; 25(3): 279-87. [http://dx.doi.org/10.1111/clr.12155] [PMID: 23560645]
- [38] Persson GR, Roos-Jansåker AM, Lindahl C, Renvert S. Microbiologic results after non-surgical erbium-doped:yttrium, aluminum, and garnet laser or air-abrasive treatment of peri-implantitis: A randomized clinical trial. *J Periodontol* 2011; 82(9): 1267-78. [http://dx.doi.org/10.1902/jop.2011.100660] [PMID: 21417591]
- [39] Wright PP, Ramachandra SS. Quorum sensing and quorum quenching with a focus on cariogenic and periodontopathic oral biofilms. *Microorganisms* 2022; 10(9): 1783. [http://dx.doi.org/10.3390/microorganisms10091783]
- [40] Krukiewicz K, *et al.* Recent advances in the control of clinically important biofilms. *Int J Mol Sci* 2022; 23(17): 9526. [http://dx.doi.org/10.3390/ijms23179526]
- [41] Sheikh BA, Bhat BA, Mir MA. Antimicrobial resistance: New insights and therapeutic implications. *Appl Microbiol Biotechnol* 2022; 106(19-20): 6427-40. [http://dx.doi.org/10.1007/s00253-022-12175-8] [PMID: 36121484]
- [42] Santonocito S, Polizzi A, Cavalcanti R, *et al.* Impact of laser therapy on periodontal and peri-implant diseases. *Photobiomodul Photomed Laser Surg* 2022; 40(7): 454-62. [PMID: 35763842]
- [43] Zhao Y, Yan Q, Wu X, Hua F, Shi B. The benefit of antimicrobial photodynamic therapy to mechanical debridement in the treatment of smokers with peri-implant diseases: A systematic review and meta-analysis. *Lasers Med Sci* 2022; 37(8): 3051-66. [http://dx.doi.org/10.1007/s10103-022-03592-2] [PMID: 35896900]
- [44] Scheeren Brum R, Apaza-Bedoya K, Labes LG, Volpato CÂM, Pimenta AL, Benfatti CAM. Early biofilm formation on rough and smooth titanium specimens: A systematic review of clinical studies. *J Oral Maxillofac Res* 2021; 12(4): e1. [PMID: 35222868]
- [45] Mendhi J, Ramachandra SS, Prasadam I, Ivanovski S, Yang Y, Xiao Y. Endogenous nitric oxide-generating surfaces *via* polydopamine-copper coatings for preventing biofilm dispersal and promoting microbial killing. *Mater Sci Eng C* 2021; 128: 112297. [http://dx.doi.org/10.1016/j.msec.2021.112297] [PMID: 34474848]
- [46] Xiang E, Gómez-Cerezo MN, Ali Y, *et al.* Surface modification of pure zinc by acid etching: Accelerating the corrosion rate and enhancing biocompatibility and antibacterial characteristics. *ACS Appl Mater Interfaces* 2022; 14(19): 22554-69. [http://dx.doi.org/10.1021/acsami.2c00918] [PMID: 35533291]
- [47] Ramachandra SS, Mahdey HM. 'Don't bite off more than you can chew'. *Dent Update* 2015; 42(7): 688. [http://dx.doi.org/10.12968/denu.2015.42.7.688] [PMID: 26630869]
- [48] Ramachandra SS. Dental implant tourism. *Aust Dent J* 2011; 56(3): 344. [http://dx.doi.org/10.1111/j.1834-7819.2011.01352.x] [PMID: 21884155]
- [49] Ramachandra SS, Rana R, Jithendra KD. Digital radiography during implant osteotomy. *J Calif Dent Assoc* 2013; 41(7): 469. [http://dx.doi.org/10.1080/19424396.2013.12222325] [PMID: 24024290]
- [50] Caton JG, Armitage G, Berglundh T, *et al.* A new classification scheme for periodontal and peri-implant diseases and conditions - Introduction and key changes from the 1999 classification. *J Periodontol* 2018; 89(Suppl. 1): S1-8. [http://dx.doi.org/10.1002/JPER.18-0157] [PMID: 29926946]